

Content available at: <https://www.ipinnovative.com/open-access-journals>

IP Indian Journal of Conservative and Endodontics

Journal homepage: <https://www.ijce.in/>

## Case Report

# Unveiling radix entomolaris: A case report and literature review on mandibular first molar anatomical variation

Shally Suri<sup>1</sup>, Rajnish K Jain<sup>1</sup>, Ambica Khetarpal<sup>1</sup>, Nikhil Bhardwaj<sup>1</sup>,  
Rachita Arora<sup>2</sup>, Avishek Singh<sup>3\*</sup>

<sup>1</sup>Dept. of Conservative Dentistry and Endodontics, PDM Faculty of Dental Sciences and research institute, PDM University, Bahadurgarh, Haryana, India

<sup>2</sup>Dept. of Periodontology and Oral Implantology, Baba Jaswant Singh Dental College, Hospital and Research institute, Ludhiana, Punjab, India

<sup>3</sup>Dept. of Public Health Dentistry, NIMS Dental College and Hospital, Jaipur, Rajasthan, India



## ARTICLE INFO

### Article history:

Received 15-07-2024

Accepted 07-08-2024

Available online 05-09-2024

### Keywords:

Anatomical variation

Endodontic treatment

Mandibular molar

Radix entomolaris

## ABSTRACT

**Introduction:** The mandibular first molar is renowned for its typical root anatomy, characterized by a mesial and distal root. Nonetheless, anatomical variations may exist, demanding a meticulous approach during endodontic procedures. The presence of an extra lingual root distally, termed radix entomolaris (RE), poses challenges to successful root canal treatment. Accurate interpretation of radiographs and precise angulations are crucial for identifying the pulp chamber and root anatomy.

**Aim:** This study aims to present a compelling case of a mandibular first molar with an additional distolingual root (RE) and to conduct a thorough survey of existing literature to determine the incidence of this anatomical feature. The objective is to emphasize the significance of recognizing and understanding this unusual root and its canal morphology in ensuring the efficacy of root canal treatment.

**Conclusion:** The failure to identify radix entomolaris (RE) can significantly impact the prognosis of endodontic treatment. Awareness and comprehension of this anatomical variation contribute to the successful outcome of root canal procedures in mandibular first molars. Proper identification, treatment planning, and meticulous execution are imperative when faced with such variations.

This is an Open Access (OA) journal, and articles are distributed under the terms of the [Creative Commons Attribution-NonCommercial-ShareAlike 4.0 License](https://creativecommons.org/licenses/by-nc-sa/4.0/), which allows others to remix, tweak, and build upon the work non-commercially, as long as appropriate credit is given and the new creations are licensed under the identical terms.

For reprints contact: [reprint@ipinnovative.com](mailto:reprint@ipinnovative.com)

## 1. Introduction

The removal of bacteria from the root canal system and the avoidance of subsequent reinfection are the main goals of endodontic treatments. This is accomplished by first biomechanically cleansing the pulp area and then hermetically sealing it with an obturating substance.

Radix entomolaris (RE), as it was named by Carabelli, was the extra root found in the mandibular first molar for the first time. The incidence of this extra third root is least prevalent in the second molar and is typically found

distolingually in the first, second, and third mandibular molars. The extra root on the mesiobuccal aspect is called radix paramolaris. Studies in the literature show that among populations of white Caucasians, Africans, Eurasians, and Indians, the prevalence of RE is less than 5%. Conversely, groups exhibiting Mongoloid characteristics, including the Chinese and the Eskimos, exhibit a higher frequency of 5–30%.<sup>1</sup> Dentist must have knowledge about prevalence, morphology, diagnosis, canal configuration and the clinical approach required for such cases.<sup>2</sup> Therefore, recognizing and addressing aberrant anatomy before and is essential to offering top-notch dental care throughout root canal therapy.<sup>3</sup> The fact that the dentist did not completely remove

\* Corresponding author.

E-mail address: [avisheksingh80a@gmail.com](mailto:avisheksingh80a@gmail.com) (A. Singh).

all of the pulp tissue and bacteria is one of the primary causes of root canal therapy failure in molars. (Cohen & Brown 2002).<sup>4</sup>

Through a review of the literature, the current study seeks to characterize the internal and exterior morphology of RE as well as assess its prevalence, origin, and clinical behavior.<sup>5</sup> Therefore, rigorous canal preparation and extremely accurate clinical and radiographic diagnostic techniques are required.<sup>6</sup> The efficacy of endodontic treatment depends on the removal of germs from the root canal system and avoidance of re-infection.<sup>7</sup> One of the reasons for partial obturation may be ignorance of the existence of the root canal's ramifications.<sup>8</sup> Notice is therefore given that certain scientists have addressed issues connected to RE without having developed clear standards for identifying macrostructure.<sup>9</sup> The clinical approach to diagnosis and endodontic treatment are also discussed and illustrated.<sup>10</sup>

## 2. Case Report

A 30-year-old patient came to the Department of Conservative Dentistry and Endodontics for the basic chief complaint of pain with respect to lower left back tooth region and with a non-contributory medical and dental history.

The pain was spontaneous, increased on lying down and present for last 3 days. Patient also experienced some sensitivity to hot foods in the tooth involved.

Deep carious lesion was observed and Tooth were tender on percussion#36.

Electric pulp test and heat test with a Gutta-percha stick gave a lingering response.

Radiolucency was seen in association with tooth #36.[Figure 1]

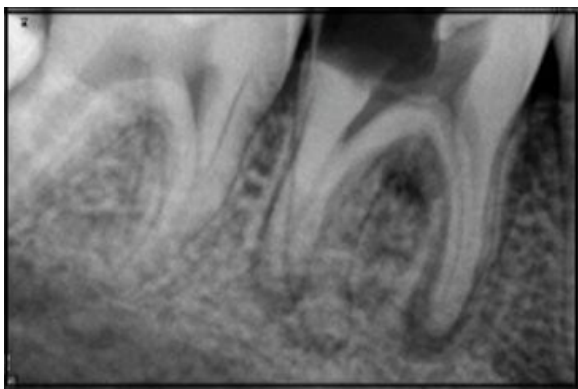


Figure 1: Preoperative

Upon complete clinical and radiographical examination, diagnosis of acute irreversible pulpitis was made.

It was decided to carry out endodontic treatment in mandibular first molar #36.

Access was gained to pulp chamber after administration of local anesthesia (2% lidocaine with 1:80,000 adrenaline). Three orifices were located in first molar #36.

Mesiobuccal, mesiolingual and distal canals were identified. Search for second distal canal was made by further exploration of pulpal floor with a DG-16 endodontic explorer.

Access cavity was refined with endo access bur (Dentsply, Switzerland) and calculation of working length with the use of an electronic apex locator of Root ZX, J.Morita was done and was confirmed by radiography. [Figure 2]

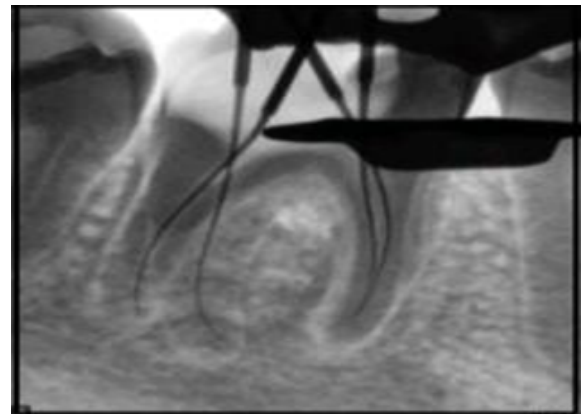


Figure 2: Working length

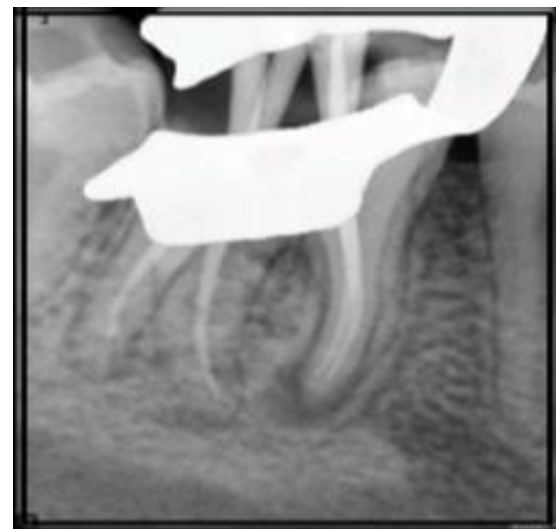

Figure 3: Master cone

Canals were cleaned and shaped using hand K files and ProTaper Next files (rotary) of Dentsply, Switzerland with EDTA of concentration as 17%. Irrigation done with sodium hypochlorite 5% and achieved the patency in all the canals which was maintained with a 10#k-file (Mani,

Japan). All the canals had separate portals of exit. Paper points were used to dry the canals, and gutta percha points were used for obturation utilizing the Cold lateral condensation technique and AH Plus sealant (Dentsply, De Trey, Germany). Radiograph is employed to evaluate the fit and placement of gutta-percha mastercone. [Figure 3]. Access cavity was filled with composite resin (tetric-N-ceram, Ivoclarvivadent).

### 3. Discussion

The clinical triad: Three-dimensional obturation, appropriate chemomechanical preparation, and a proper diagnosis are essential for the successful root canal treatment.<sup>1</sup>

Carlsen and Alexandersen categorized RE into 4 types: According to location of cervical portion.

Types A and B: 2 or 1 distal root (normal) component and the cervical part are present distally.

Type C: the mesially situated cervical region

Type AC: the center location of the cervical section lies between the mesial and distal root components. De Moor et al. divided RE into three categories:

Type I: with a root canal or straight root

Type II: a straight root or root canal with a curving opening that first persists

Type III: has a first curve in the root canal's coronal third and a second curve that starts in middle and continues at apical third.

This classification is further modified by adding two more newly defined variants of RE termed.

1. Type 1: Small, where the length is half of that of the distobuccal root.
2. Type 2: Conical, where it is even smaller than the small type and has no root canal.<sup>2</sup>

Possible effort should be made on locating of any extra root in the mandibular 1st molars.<sup>3</sup> Predictably, Following the fundamentals of access, cleaning and shaping, and also obturation of the whole of the root canal system is essential for a successful root canal procedure. Perhaps the most significant of the three is the principle of (straight) line access (Christie & Thompson 1994). For locating and proper access of the root canal, RE is situated distolingually, modifying the traditional triangle entrance cavity to a trapezoidal shape.<sup>4</sup> Although many approaches utilized in knowing RE can be ascribed to the range of outcomes observed.<sup>5</sup> Because the root canal wall of the RE was extremely thin, a straight path to these root canals is essential for proper shape and cleaning.<sup>6</sup> Visual aids like a loupe, intraoral camera, or dental microscope can be useful.

Vertucci (1984) found that type 2 and type 4 lesions were more common in the mesial roots of mandibular molars, accounting for 28% and 51%, respectively. 70% of the distal

roots are in type 1 canals. Type 1 root canal designs were found in 54% of distal roots, type 2 in 44%, and type 4 in 43% of mesial roots by Sert et al. (2004). In the current state, most mesial roots of the mandibular first molars had two canals (77%), and three canals in 20%. Most common were type 4 (55%) and type 2 (23%) in mesial roots.<sup>7</sup> Type 1 in 54% of distal roots, type 2 in 44% of mesial roots and type 4 in 43%. The majority of the mandibular first molars in this study had two canals in their mesial roots (77%), whereas 20% had three canals. In mesial roots, type 2 (23%) and type 4 (55%) were the most prevalent. 54% of distal roots are type 1. Therefore, when treating the mandibular first molar endodontically, it is crucial that the dentist always search for a fourth canal.<sup>8</sup> The current study's findings concur with those of Vertucci (1984) and Sert et al. (2004).<sup>9</sup> In order to prevent procedural errors, step-by-step procedures should be followed.<sup>10</sup>

### 4. Conclusion

Additionally, the potential of an other root needs to be carefully addressed and searched for. Correct alignment and interpretation of radiographs enable identifies chamber and anatomy of the root. Dentists must possess the necessary understanding of the morphology, etiology, prevalence and therapeutic approach to receive the best endodontic care.

### 5. Source of Funding

None.


### 6. Conflict of Interest


None.


### References

1. Arora A, Arya A, Chauhan L, Thapak G. Radix entomolaris: Case report with clinical implication. *Int J Clin Pediatr Dent.* 2018;11(6):536–8.
2. Sinha DJ, Mahesh S, Jaiswal N, Vasudeva A. Radix entomolaris: A report of two cases. *Bull Tokyo Dent Coll.* 2016;57(4):253–8.
3. AKGarg, Tewari RK, Jindal MK, Agrawal N. Radix entomolaris: A clinical challenge. *Int J Clin Pediatr Dent.* 2010;3(2):105–6.
4. De Moor R, Deroose C, Calberson FLG. Radix entomolaris in mandibular first molars is an endodontic challenge. *Int Endod J.* 2004;37(11):789–99.
5. Girelli CFM, De Lima C, Marceliano-Alves M, Coelho RG, Lacerda GP, Lacerda M, et al. Radix entomolaris, an anatomical variation of mandibular molars: clinically relevant considerations: Radix entomolaris, umavariaçãonanatômicaemmolaresinferiores. *Braz J Dev.* 2022;8(11):73346–57.
6. Paulaiian B, Thomas B, Nishad A, Sam J. Case reports and clinical guidelines for managing radix entomolaris. *J Pharm Bioallied Sci.* 2016;8(5):160–3.
7. Yew SC, Chan K. A retrospective study of endodontically treated mandibular first molars in a Chinese population. *J Endod.* 1993;19(9):471–3.
8. Chen G, Yao H, Tong C. Investigation of the root canal configuration of mandibular first molars in a Tawain Chinese population. *Int Endod J.* 2009;42(11):1044–9.

9. Sarangi P, Uppin VM. Mandibular first molars with a radix entomolaris: an endodontic dilemma. *J Dent (Tehran)*. 2014;11(1):118–22.
10. Calberson FL, De Moor R, Deroose CA. The radix entomolaris and paramolaris: clinical approach in endodo Anatomic variations of lower first permanent molar roots in endontics. *J Endod*. 2007;33(1):58–63.

**Nikhil Bhardwaj**, Post Graduate Resident  <https://orcid.org/0009-0003-4085-6057>

**Rachita Arora**, Post Graduate Resident  <https://orcid.org/0009-0001-9763-7643>

**Avishek Singh**, Post Graduate Resident  <https://orcid.org/0000-0003-0635-9682>

### Author biography

**Shally Suri**, Post Graduate Resident  <https://orcid.org/0009-0007-8398-4429>

**Rajnish K Jain**, Professor and Head

**Ambica Khetarpal**, Professor

**Cite this article:** Suri S, Jain RK, Khetarpal A, Bhardwaj N, Arora R, Singh A. Unveiling radix entomolaris: A case report and literature review on mandibular first molar anatomical variation. *IP Indian J Conserv Endod* 2024;9(3):155-158.